



STANDARD ARTICLE

Clinicopathologic and radiographic features in 33 cats with aspiration and 26 cats with bronchopneumonia (2007-2017)

Jonathan D. Dear¹  | William Vernau² | Eric G. Johnson³ | Sean E. Hulsebosch¹ | Lynelle R. Johnson¹ 

¹Department of Medicine and Epidemiology, School of Veterinary Medicine, University of California, Davis, California

²Department of Pathology and Microbiology, School of Veterinary Medicine, University of California, Davis, California

³Department of Surgical and Radiological Sciences, School of Veterinary Medicine, University of California, Davis, California

Correspondence

Jonathan D. Dear, Department of Medicine and Epidemiology, School of Veterinary Medicine, University of California, One Shields Avenue, Davis, CA 95616.
 Email: jddear@ucdavis.edu

Abstract

Background: Aspiration pneumonia (AP) and bronchopneumonia (BP) are poorly characterized diseases in cats that share clinical similarities to inflammatory airway disease (IAD).

Objectives: Describe clinicopathologic, radiographic, and microbiologic features in cats with AP and BP and compare findings to those in cats with IAD.

Animals: Thirty-three cats with AP and 26 with BP; 44 cats with IAD.

Methods: Retrospective case-control study. Results extracted for all cats included signalment, physical examination findings, historical details, and potential risk factors for aspiration. Diagnostic test results were summarized including CBC, bronchoalveolar (BAL) fluid analysis and microbial culture. Radiographs were reviewed in masked fashion and scored for severity. Results of BAL fluid analysis were assessed for evidence of septic inflammation.

Results: Cats with AP were less likely to be presented for evaluation of cough ($P < .001$) and more likely to be hypothermic ($P = .01$) than were cats with IAD or BP. Median duration of signs was significantly shorter in cats with AP (12 days) compared to cats with BP or IAD (270 and 180 days; $P = .01$). Radiographically, cats with AP were more likely to have an alveolar pattern and higher total score than were cats with BP or IAD. *Mycoplasma* spp. were the organisms most commonly cultured from BAL fluid in cats with BP, but were not cultured from any cats with AP.

Conclusion and Clinical Importance: Pneumonia must be distinguished from IAD in cats with cough and AP should be considered in cats with acute onset of tachypnea.

KEYWORDS

aspiration pneumonia, bronchopneumonia, feline, mycoplasma, pneumonia

1 | INTRODUCTION

Cough is a common reason for presentation of cats to veterinary clinics and can be caused by both inflammatory airway disease (IAD) and pneumonia. The term pneumonia refers to acute inflammation of

Abbreviations: AP, aspiration pneumonia; BAL, bronchoalveolar lavage; BP, bronchopneumonia; IAD, inflammatory airway disease; IQR, interquartile range.

This is an open access article under the terms of the Creative Commons Attribution-NonCommercial License, which permits use, distribution and reproduction in any medium, provided the original work is properly cited and is not used for commercial purposes.

© 2020 The Authors. *Journal of Veterinary Internal Medicine* published by Wiley Periodicals LLC. on behalf of the American College of Veterinary Internal Medicine.

the alveoli and bronchioles and can result from multiple insults to the gas exchange region.¹ Pneumonia can be classified by the infectious organism (virus, bacteria, fungus, or protozoa) or as an interstitial disease and also can be categorized by clinical features such as aspiration or foreign body associated.^{2,3} Aspiration events can lead to pneumonitis, an aseptic inflammation caused by the acidity of gastric contents, or result in pneumonia when bacterial infection develops.⁴ Differentiation of these 2 disorders is challenging without collection of an airway sample, which might not always be possible in a cat with respiratory dysfunction. In contrast, bronchopneumonia (BP) develops without a clear aspiration event when bacteria reach the gas exchange region by inhaled aerosol droplets or via hematogenous routes.

Inflammatory airway disease is a well-described cause of cough in cats, but pneumonia has not been as well characterized in cats. Cats appear to be at lower risk for aspiration injury, compared to dogs, perhaps because of more robust airway defenses such as laryngospasm.⁵ In human patients, asthma, chronic bronchitis, and BP are linked and studies suggest that airway inflammation can be both a cause and consequence of pneumonia.^{6,7} Currently, no evidence suggests that IAD is a risk factor for BP in cats.

Limited peer-reviewed literature describes BP or aspiration pneumonia (AP) in cats. Two retrospective necropsy studies described pneumonia in cats, but no airway sampling or microbiology was performed, and thus the causative organisms were not identified.^{8,9} Similarly, a recent study presented clinical findings of cats diagnosed with AP but lacked airway cytology and culture results.³ Two studies reported an incidence of pneumonia in 15% to 22% of cats that had bronchoscopy performed for evaluation of cough,^{10,11} but few studies have documented the clinical features and bronchoscopic findings in cats diagnosed with bacterial pneumonia.

Our objective was to characterize the clinicopathologic features, radiographic findings, and bronchoalveolar lavage (BAL) fluid cytology and culture results in cats with confirmed BP and AP using cats with IAD as a control group. We also sought to identify the bacteria most commonly involved in pneumonia in cats and to define the risk factors for aspiration in our population of cats. We hypothesized that cats with both AP and BP would have shorter duration of clinical signs before presentation, altered body temperature, and variable radiographic changes compared to cats diagnosed with IAD during the same time period.

2 | MATERIAL AND METHODS

The electronic medical record database at the William R. Pritchard Veterinary Medical Teaching Hospital was searched from January 2007 to January 2017 for a clinical diagnosis of “pneumonia,” “aspiration pneumonia,” or “bronchopneumonia” in cats, and cats subsequently were divided into groups of AP and BP based on detection of risk factors.^{3,12,13} Therefore, a diagnosis of AP required a history of a concurrent event or disease predisposing to aspiration and radiographic evidence of a cranioventral pulmonary distribution pattern. Inclusion criteria for a diagnosis of BP included cytologic

evidence of septic inflammation or clinically relevant bacterial or mycoplasmal culture on airway sampling (either BAL or endotracheal lavage). Critically, cats in this group lacked identification of recognizable risk factors associated with aspiration injury. Exclusion criteria for both groups were administration of glucocorticoids, prior diagnosis of IAD, and diagnosis of neoplasia or fungal disease. A control group consisted of a cohort of cats diagnosed with IAD during the time period of the study. Inclusion criteria for control cats were clinical signs of lower respiratory tract disease, and either neutrophilic, eosinophilic, or mixed lower airway inflammatory disease in the absence of intracellular organisms or clinically relevant microbial growth in BAL culture. All control cats had bronchoscopy performed.

Results extracted from the medical record included signalment, pertinent historical details (including type and duration of clinical signs, and presence of events previously recognized as risk factors for aspiration in dogs, including recent anesthesia, gastrointestinal signs, neurologic disease or laryngeal disease).^{12,14} Physical examination findings (including body temperature, respiratory rate, thoracic auscultation, body weight, and body condition score) and results of CBC, heartworm and retrovirus testing, fecal examination and PCR panels for feline respiratory disease, were collected when available. Outcomes were recorded including resolution of clinical signs or death or euthanasia because of respiratory disease.

Radiographic interpretations from the time of diagnosis were evaluated, and radiographs were retrospectively reviewed by a board-certified radiologist (E. G. Johnson) blinded to diagnosis and outcome of each cat. Radiographs were scored using a 0 to 9 rubric previously used in cats with lower airway disease.¹⁵⁻¹⁷ (Table 1). Additionally,

TABLE 1 Radiograph scoring rubric used in masked, case-controlled, retrospective review

Alveolar	Bronchial	Interstitial
0—Absence of pattern	0—Absence of pattern	0—Absence of pattern
1—Mild (slight, localized alveolar pattern)	1—Mild (primary bronchi visible)	1—Mild (mild interstitial framework visible)
2—Moderate (moderate, bilateral signs of alveolar pattern)	2—Moderate (secondary bronchi visible)	2—Moderate (interstitial framework distinguishable from a bronchial pattern)
3—Severe (clearly apparent bilateral signs of alveolar pattern or lobar consolidation)	3—Severe (tertiary bronchi visible)	3—Severe (clearly apparent interstitial pattern)

Note: A total radiographic score was provided for each cat by adding the cumulative scores from each radiographic pattern. Radiographs were also assessed for the presence bronchiectasis, enlargement of pulmonary vessels, presence of airway mineralization, and hypo- or hyperinflation. Total score = alveolar + bronchial + interstitial score.

radiographs were assessed for presence or absence of bronchiectasis, enlargement of pulmonary vessels, presence of airway mineralization, and hypo- or hyperinflation.

Bronchoscopy was performed in some cats using either a 2.8 mm × 70 cm videoendoscope with a 1.2 mm channel (Karl Storz Flex XC, Goleta, California) or a 3.8 mm × 55 cm videoendoscope with a 1.2 mm channel (Olympus BF3C160, Center Valley, Pennsylvania). Cats were premedicated with oxymorphone 0.03 to 0.05 mg/kg IM or butorphanol 0.2 to 0.4 mg/kg IM, atropine 0.02 mg/kg IM, and dexmedetomidine 5 to 10 µg/kg IM in fractious animals. Bronchoscopy was performed under IV propofol anesthesia with an induction dosage of 6 mg/kg followed by 0.1 to 0.4 mg/(kg min) as a continuous rate infusion. All cats were preoxygenated before the procedure, pretreated with terbutaline 0.01 mg/kg SC to limit bronchoconstriction, and oxygenation was maintained by jet ventilation at 180 breaths/min. Pulse oximetry, ECG, and blood pressure were monitored throughout the procedure in all cats. Bronchi were evaluated sequentially from left to right, then the bronchoscope was removed from the airways to irrigate the channel with sterile saline and wipe debris from the outer surface, and the bronchoscope was reinserted to complete BAL at a specific site or sites chosen by the endoscopist. Bronchoalveolar lavage was performed by instilling 3 to 5 mL of warmed, sterile saline through the biopsy channel of the endoscope, irrigating the channel with 2 to 3 mL of air, and immediately applying hand suction to recover fluid that had been in contact with the bronchoalveolar space. Lavage was performed at 1 to 3 sites and fluid was submitted for cytologic analysis and culture within 1 hour of collection. Bronchoalveolar lavage fluid samples from different sites were analyzed separately by cytologic assessment and were pooled for submission of aerobic, anaerobic, and *Mycoplasma* cultures at the discretion of the attending clinician. Aerobic bacterial cultures were performed on both 5% blood and MacConkey agar, anaerobic bacterial cultures were performed on PRAS *Brucella* blood agar, and mycoplasmal cultures were performed on *Mycoplasma* growth media inoculated with thallium acetate and penicillin. Microbial growth that developed only in tryptic soy (enrichment) broth was not considered to be clinically relevant.

Bronchoalveolar lavage fluid cytology results were extracted from the medical record, including the highest total nucleated cell count/µL (TNCC/µL), highest and lowest percentage of neutrophils, and percentage of eosinophils. Airway inflammation was characterized as eosinophilic in BAL samples with eosinophil differential cell count percentages >20% and as neutrophilic with neutrophil differential cell count percentages >7%.^{18,19} Cytology samples from cats diagnosed with pneumonia were reassessed cytologically for the severity of neutrophil karyolysis and the presence or absence of septic inflammation (intracellular bacteria or *Mycoplasma*-like organisms or both) by a board-certified clinical pathologist (W. Vernau) who was aware of the clinical diagnosis of pneumonia but unaware of group classification, microbiology results, and outcome. Microscopic assessment for the presence of bacteria and *Mycoplasma*-like organisms was done using both a ×60 and ×100 objective lens.

2.1 | Statistical analysis

Data were analyzed for normality using the Shapiro-Wilk test. Data are presented as median (interquartile range). Continuous data were compared between 2 groups using the Mann-Whitney *U* test and among 3 groups using a 1-way analysis of variance, as appropriate. Categorical data were evaluated using chi-squared tests. All post hoc analyses were performed using Tukey's test for pairwise comparisons. All statistical analyses were performed using commercially available software (SAS v. 9.4, Cary, North Carolina). *P* values <.05 were considered significant.

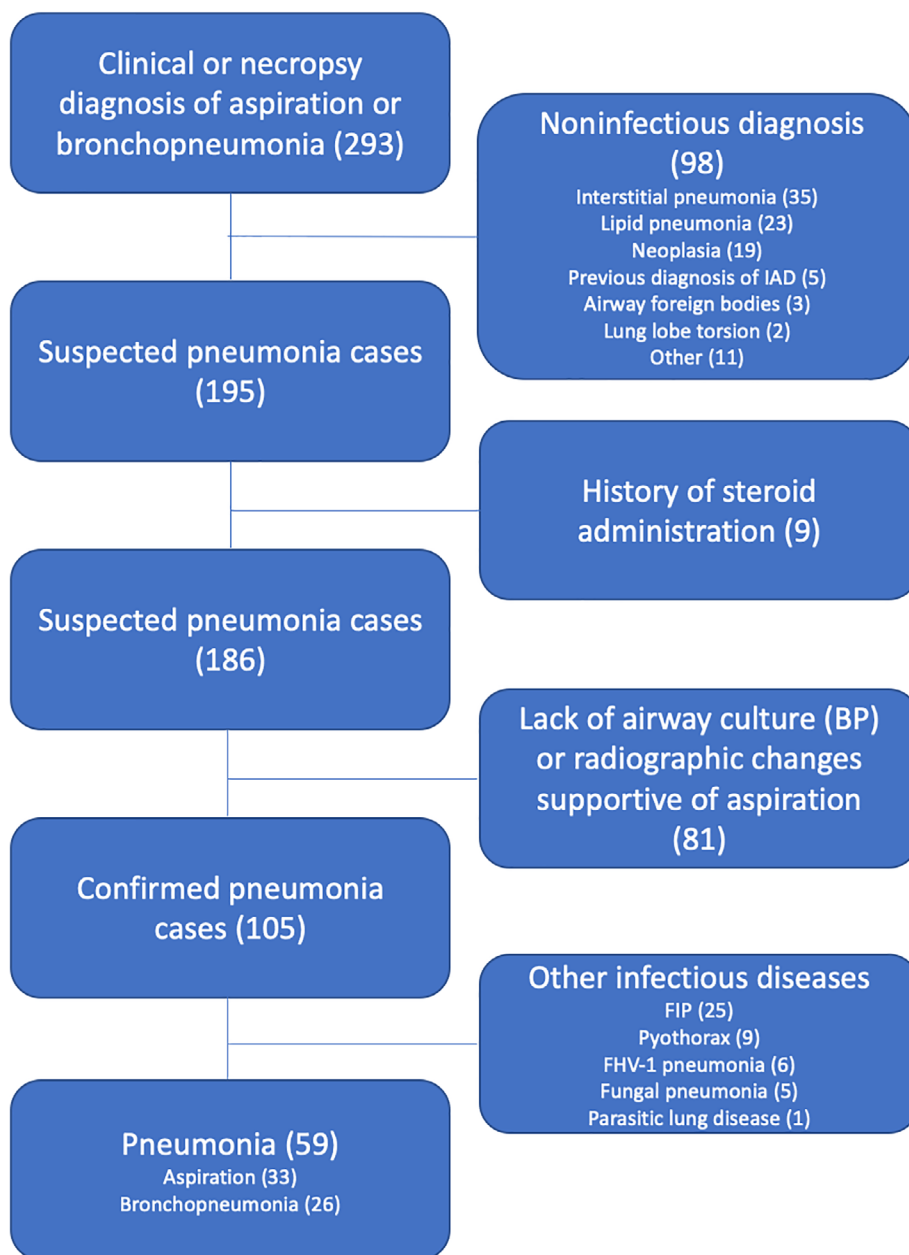
3 | RESULTS

Search of the electronic medical records yielded 293 cats with a preliminary diagnosis of pneumonia (Figure 1). Ninety-three cats were excluded because of alternate diagnoses including interstitial pneumonia (*n* = 35), lipid pneumonia (*n* = 23), neoplasia (*n* = 19), IAD (*n* = 5), airway foreign bodies (*n* = 3), lung lobe torsion (*n* = 2), and other non-infectious lung diseases (*n* = 11). Nine cats were excluded because of treatment with glucocorticoids at the time of evaluation. Eighty-one cats were excluded because of lack of either airway culture (BP group) or supportive radiographic changes (AP group). Forty-six cats were excluded because of a diagnosis of other infectious respiratory diseases including feline infectious peritonitis (*n* = 25), pyothorax (*n* = 9), feline herpesvirus-1 pneumonia (*n* = 6), fungal pneumonia (*n* = 5), and parasitic lung disease (*n* = 1).

Cats included in the study consisted of 33 with AP and 26 with BP. For all cats diagnosed with AP, diagnosis was based on consistent radiographic findings and identification of risk factors. Documentation of resolution of clinical signs by recheck examination or telephone follow-up was available for 20/33 cats at a median of 10 days post-discharge (interquartile range [IQR], 3-21 days). Thirteen cats with AP either died or were euthanized because of their respiratory disease. In 8 cats, AP was confirmed histologically at necropsy and culture results were available in 3. Additionally, 7 cats with AP had airway samples collected, 1 of which had necropsy confirmation of the condition. Cats with BP (*n* = 26) were diagnosed either by airway fluid cytology findings of septic, suppurative inflammation (23/26), or positive airway bacterial culture (21/26). Four cats with BP died or were euthanized as a consequence of their respiratory disease, and resolution of clinical signs after treatment was recorded in 22/26 cats after a median interval of 23 days (IQR, 14-30 days). The control group consisted of 44 cats with IAD that lacked septic inflammation cytologically and had no clinically relevant growth on BAL fluid microbial culture.

For all cats, cough was the most common presenting sign (63/103; 61%) and was significantly more common in cats with BP (25/26; 96%) or IAD (30/44; 68%) compared to AP (8/33; 24%, *P* < .001). Tachypnea was reported in 38/103 cats (37%) and was more common in cats with AP (17/33; 52%) compared with BP (10/26; 38%) and IAD (11/44; 25%) but this difference was not

FIGURE 1 CONSORT (Consolidated Standards of Reporting Trials) diagram reflecting search and inclusion/exclusion criteria to reach study population



significant ($P = .06$). Wheezing was reported in 24/103 (23%) cats and was more common in cats with BP (13/26; 50%) than in cats with AP (5/32; 16%) or IAD (6/44; 14%, $P = .003$). Duration of clinical signs before presentation was significantly different between groups (median duration: AP, 12 days; BP, 270 days; IAD, 180 days; $P = .01$) and duration was significantly longer in cats with IAD (IQR, 60-360 days) compared with cats with AP (IQR, 3-90 days; $P < .05$), but not when compared to cats with BP (IQR, 90-570 days; Figure 2).

The most common risk factor for aspiration was gastrointestinal disease (25/33 cats). Esophageal disease was diagnosed in 16 cats, including megaesophagus (7 cats), esophageal stricture (5 cats), esophageal dysmotility or chronic regurgitation (3 cats), and hiatal hernia (1 cat). Other risk factors included acute or chronic vomiting in 4 and 6 cats, respectively, a tracheoesophageal fistula in 1 cat, and palate

defects in 1 cat. Nine cats diagnosed with AP had a history of general anesthesia within 3 days of diagnosis with pneumonia. One cat in the AP group was being evaluated for seizures when diagnosed. Finally, 1 cat was diagnosed with a laryngeal carcinoma and had received palliative radiation treatment 3 months before diagnosis of AP. Four cats had multiple risk factors.

Age did not differ among cats with AP (median = 7 years; IQR, 1-11 years), BP (median = 9 years; IQR, 3.5-13 years), and IAD (median = 5 years; IQR, 0.75-18 years; $P = .14$). Cats with AP had significantly lower body weight (median = 4.0 kg; IQR, 2.8-4.6 kg) than did cats diagnosed with BP (median = 5.25 kg; IQR, 3.7-6.5 kg) or IAD (median = 4.8 kg; IQR, 4.1-5.5 kg; $P < .001$). On physical examination, a significant difference was found in the proportion of cats that were hypothermic at presentation (AP, 12/30; BP, 3/23; IAD, 5/39; $P = .01$) and cats diagnosed with AP were significantly more

likely to be hypothermic compared with cats with IAD ($P < .05$). Cats with BP had significantly lower respiratory rates (RR) at presentation (median, 36/min; IQR, 30-44/min) than did cats with AP (median,

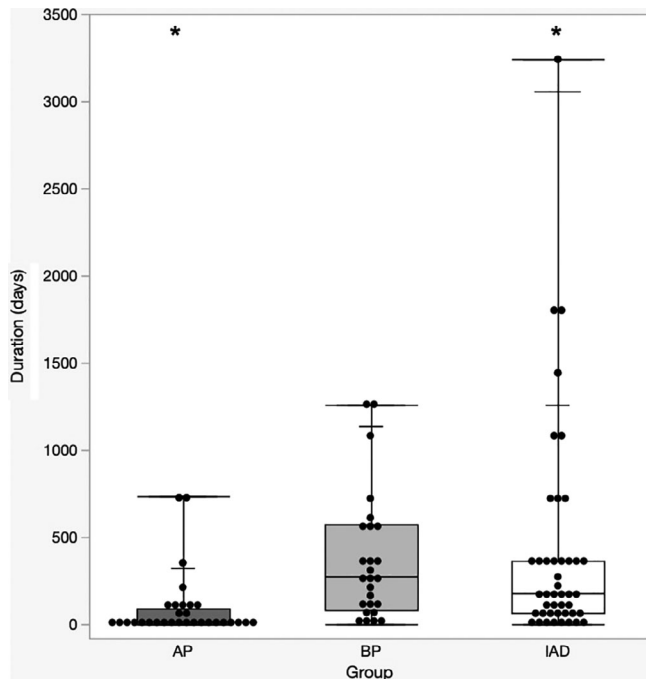


FIGURE 2 Dot plot with box and whiskers displaying duration of reported clinical signs by group: aspiration (AP), bronchopneumonia (BP), and inflammatory airway disease (IAD). Dots indicate individual cats, central bars indicate median, and boxes indicate interquartile range. Whiskers indicate range and shorter horizontal bars indicate quantiles. Duration of clinical signs was significantly longer in cats with IAD compared to AP (indicated by *, $P < .05$)

42/min; IQR, 35-66/min) or IAD (median, 54; IQR, 40-66/min; $P = .003$), but similar numbers of cats were tachypneic (RR > 40 /min) in each group.

A CBC was performed in 86/103 cats within 1 week of diagnosis, and peripheral neutrophilia ([neutrophils > 9000]/ μ L) was present in 28/86 (33%) cats. Cats with AP and BP had significantly higher neutrophil counts (median, 7775/ μ L; IQR, 6037-12 916/ μ L) than did cats with IAD (median, 5545/ μ L; IQR, 3910-9214/ μ L; $P = .003$; Table 2). Cats with AP were significantly more likely to have a left shift (15/26; 58%) than were cats with IAD (5/38; 13%, $P < .05$), but not compared to those with BP (6/22; 27%). No significant differences were found between peripheral lymphocyte or eosinophil counts among groups.

Retrovirus testing was performed in 26/59 cats with pneumonia, and 1 cat in the BP group was positive for feline immunodeficiency virus (FIV) antibodies. Seventeen cats with pneumonia were tested for heartworm antibodies, 3 had fecal testing, and 4 had respiratory PCR panels performed on BAL fluid; all were negative.

Thoracic radiographs were available for review in 30/33 cats with AP, 23/26 cats with BP, and 42/44 cats with IAD. Radiographs were classified as normal in 1 cat with IAD. Total radiographic scores were significantly different among groups (median scores: AP, 4; BP, 4; IAD, 3; $P < .02$) with significantly higher total scores in cats with AP (IQR, 3-6) compared to cats with IAD (IQR, 1-4; $P < .05$) but no difference from cats with BP (IQR, 2-6; Table 3). Cats with IAD were more likely to have a diffuse radiographic pattern whereas cats with AP were more likely to have multifocal distribution of disease ($P = .002$). Cats diagnosed with AP were more likely to have an alveolar pattern (24/30; 80%) compared with cats with IAD (15/42; 36%; $P < .05$) but this was not significantly different when compared to cats with BP (14/23; 61%; Figure 3). Overall, 13 cats had radiographic evidence of

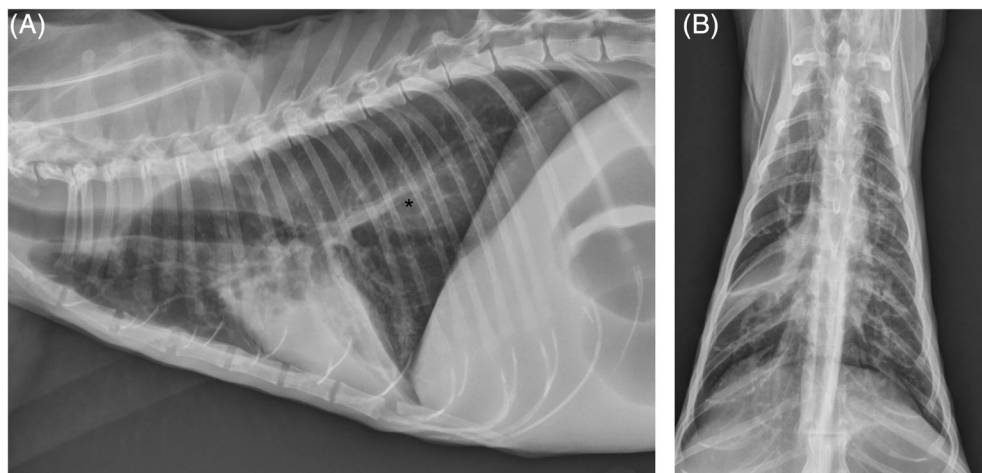


FIGURE 3 Left lateral (A) and dorsoventral (B) radiographs of an 11-year-old male castrated domestic medium hair cat with aspiration pneumonia diagnosed radiographic findings and a history of chronic vomiting due to an annular jejunal obstructive mass found at necropsy. These radiographs are characteristic of cats diagnosed with aspiration pneumonia that generally had a multifocal alveolar to lesser bronchial pattern with a higher overall radiographic score. In these radiographs, there is an alveolar pattern affecting the cranioventral lobes with complete volume loss of the right middle lung lobe. There is also gas and fluid filling (indicated by *) of the esophagus as well as gas distention of the stomach and bowel loops in the visible abdomen. The pulmonary vasculature is unremarkable

TABLE 2 Selected blood count results from cats with aspiration pneumonia (AP), bronchopneumonia (BP), and inflammatory airway disease (IAD)

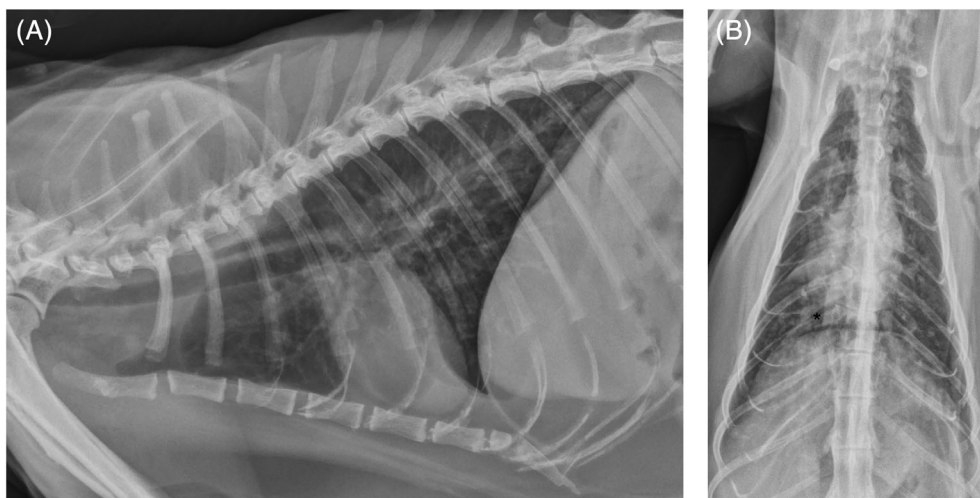
	Reference interval	AP (n = 25)	BP (n = 24)	IAD (n = 38)	P value
Neutrophil count (cells/ μ L)	2000-9000 cells/ μ L	8214 (6166-12 273)	7648 (5908-13 558)*	5545 (3910-9214)*	.01
Neutrophilia	>9000 cells/ μ L	12/26	9/22	7/38	.04
Band count (cells/ μ L)	Rare	306 (0-1144)*	0 (0-174)	0 (0-0)*	.007
Left shift	>Rare	15/26*	6/22	5/38*	.003

Note: Data are presented as median (interquartile range). Asterisks indicate significance by post hoc comparisons ($P < .05$).

TABLE 3 Radiographic distribution and scoring in cats diagnosed with aspiration pneumonia (AP), bronchopneumonia (BP), and inflammatory airway disease (IAD)

		AP (n = 30)	BP (n = 23)	IAD (n = 42)	P value
Distribution	Normal	0 (0%)	0 (0%)	1 (2%)	.001
	Focal	4 (13%)	3 (13%)	2 (5%)	.001
	Multifocal	18 (60%)*	5 (22%)	7 (17%)*	.001
	Diffuse	8 (27%)*	15 (65%)	31 (74%)*	.001
Bronchial	Number	18 (60%)	20 (87%)	33 (79%)	.06
	Score	1 (0-2)*	2 (1-3)*	1 (1-2)	.008
Interstitial	Number	21 (70%)	11 (48%)	20 (48%)	.13
	Score	2 (0-2)*	0 (0-1)	0 (0-1)*	.04
Alveolar	Number	24 (80%)*	14 (61%)	15 (36%)*	.001
	Score	2 (1-3)*	1 (0-3)	0 (0-2)*	.001
Total score		4 (3-6)*	4 (2-6)	3 (1-4)*	.02

Note: Data are presented as number of individuals (percentage) or median (interquartile range). Asterisks indicate significance by post hoc comparison ($P < .05$).

**FIGURE 4** Left lateral (A) and dorsoventral (B) radiographs from a 15-year-old MC domestic short hair cat presented for weight loss, periuria, and a chronic wet cough of 3 years in duration. These radiographs are characteristic of those from cats with BP in that there is a more prominent bronchial pattern with bronchiectasis (indicated by *). There is a wedge-shaped soft tissue opacity causing border effacement of the cardiac silhouette in the region of the right middle lung lobe of the dorsoventral projection consistent with right middle lung collapse. The cardiac silhouette and pulmonary vasculature are within normal limits. Septic suppurative inflammation was found in BAL cytology and a mixed infection was detected on culture including *Mycoplasma* spp., *Pasteurella stomatis*, *Streptococcus viridans*, *Actinomyces* spp., and *Fusobacterium* spp. This cat was diagnosed with bronchopneumonia given the lack of known history of risk factors associated with aspiration. BAL, bronchoalveolar lavage; BP, bronchopneumonia

right middle lung lobe consolidation (AP, 3/30; BP, 5/23; IAD, 5/42; $P = .46$). No significant difference was found in the number of cats assessed as having a bronchial pattern (AP, 18/30; 60%; BP, 20/23;

87%; IAD, 33/42; 79%; $P = .06$) but cats with BP had higher bronchial scores (2; IQR, 1-3) compared to cats with AP (1; IQR, 0-2; $P < .05$) but not IAD (Figure 4).

	AP (n = 6)	BP (n = 25)	IAD (n = 44)	P value
TNCC/ μ L	1100 (600-1300)	2700 (1530-5240)*	1300 (800-1970)*	.05
Neutrophil %	66 (38-75)	85 (45-94)*	24 (12-61)*	<.001
Eosinophil %	11 (6-16)*	3 (1-12)\$	40 (15-56)*\$	<.001

Note: Data are presented as median (interquartile range). Asterisks and dollar signs indicate significance by post hoc comparisons ($P < .05$).

Abbreviation: TNCC, total nucleated cell count.

Radiographic evidence of bronchiectasis was observed in all groups (AP, 14/30; 47%; BP, 11/23; 49%; IAD, 16/42; 38%) and prevalence did not differ among groups ($P = .67$). No significant difference was found in the presence of hypo- or hyperinflation ($P = .08$) or bronchial mineralization ($P = .2$) among groups.

One cat with AP and 1 cat with BP had airway sampling performed by endotracheal lavage. Bronchoscopic BAL was performed in 6/33 cats with AP, 25/26 cats with BP, and in all cats with IAD. Neutrophils were too degenerate in 1 cat with AP to determine total cell or differential counts. In the remaining samples, median total nucleated cell counts (TNCC) were increased in all 3 groups, and cats with BP had significantly higher TNCC (3000 cells/ μ L; IQR, 1530-5240/ μ L) than did cats with IAD (1300 cells/ μ L; IQR, 800-1970/ μ L; $P < .05$), but the difference was not significant when compared to AP (1100 cells/ μ L; IQR, 600-1300/ μ L; Table 4). Among cats that had bronchoscopy performed, neutrophilic inflammation was present in 6/6 cats with AP, 24/25 (96%) cats with BP, and 36/44 (82%) cats with IAD. Neutrophil percentage was significantly lower in cats with IAD compared to cats with BP ($P < .05$) but not compared to cats with AP. On review of BAL fluid slides, septic inflammation was observed cytologically in 3/5 BAL samples from cats with AP and in 25/25 (100%) BAL samples from cats with BP. Median BAL fluid neutrophil differential cell count percentage in cats with negative culture (38%; IQR, 14%-67%) was significantly lower than in cats with a positive culture (82%; IQR, 44%-94%; $P < .001$).

Aerobic bacterial culture was performed on BAL fluid ($n = 6$), endotracheal wash fluid ($n = 1$), and tissue samples obtained at necropsy ($n = 2$) in 9 cats with AP. Positive aerobic culture results were obtained in 6 cats and yielded mixed growth in 3 cats (hemolytic *E coli*, *Klebsiella pneumoniae*, and *Enterococcus faecalis* in 1 cat, *Pasteurella multocida* and *Streptococcus viridans* in another and *Pasteurella multocida*, *Pseudomonas aeruginosa*, *Fusobacterium* spp., and *Clostridium* spp. in the third cat). Three cats had pure growth of coagulase negative *Staphylococcus* spp., *Enterococcus faecium*, and *Myroides* spp., respectively. *Mycoplasma* cultures were negative in 8/8 cats with AP.

Anaerobic bacterial cultures were positive in 3/9 cats with AP; 2 had pure growth, 1 each of *Actinomyces* spp. and *Peptostreptococcus* spp. and 1 had mixed growth of *Peptostreptococcus anaerobius* and *Fusobacterium* spp. (Table 5). Two cats with negative airway cultures had positive responses to amoxicillin-clavulanic acid, and cats that did not have airway sampling performed responded clinically to treatment with various antibiotics including azithromycin, amoxicillin or amoxicillin-clavulanic acid, cefazolin, enrofloxacin, or a combination thereof.

TABLE 4 Bronchoalveolar lavage cytology results from cats diagnosed with aspiration pneumonia (AP), bronchopneumonia (BP), and inflammatory airway disease (IAD)

TABLE 5 Culture results from airway lavage or necropsy samples in cats diagnosed with aspiration pneumonia (AP) and bronchopneumonia (BP)

	AP	BP
Aerobic culture	n = 9	n = 26
Gram-positive		
<i>Corynebacterium</i> spp.	0	2
<i>Enterococcus</i> spp.	2 (1)	2
<i>Streptococcus</i> spp.	1	7 (2)
<i>Staphylococcus</i> spp.	1 (1)	1
Gram-negative		
Enterics		
<i>E coli</i>	1	1
<i>Klebsiella pneumoniae</i>	1	0
Nonenterics		
<i>Acinetobacter</i> spp.	0	1
<i>Bordetella bronchiseptica</i>	0	1
<i>Myroides</i> spp.	1 (1)	1
<i>Pasteurella</i> spp.	2	8 (1)
<i>Pseudomonas aeruginosa</i>	1	2 (2)
Unclassified nonenteric	0	1 (1)
Mycoplasma culture	n = 8	n = 26
<i>Mycoplasma</i> spp.	0	11 (2)
Anaerobic culture	n = 9	n = 24
<i>Actinomyces</i> spp.	1 (1)	2
<i>Peptostreptococcus</i> spp.	1 (1)	2
<i>Clostridium</i> spp.	1	1
<i>Bacteroides</i> spp.	0	3
<i>Fusobacterium</i> spp.	1	2

Note: Numbers in parentheses indicate the number of cats with a single bacterium cultured.

In cats with BP, aerobic bacterial cultures were positive in 20/26 (77%) cats, anaerobic cultures in 7/24 (29%), and *Mycoplasma* spp. in 11/26 (42%). Fourteen cats had mixed growth on culture whereas 6 had growth of a single bacterial species on culture. Two of the 11 cats positive for *Mycoplasma* had pure growth. Samples from 3 cats with *Mycoplasma* infections were submitted for speciation, all 3 had growth of *M. arginini*, 2 had growth of *M. canis* and 1 had growth of *M. felis*. The cat that had all 3 *Mycoplasma* species isolated had no aerobic or anaerobic growth on culture. No cats with BP had growth only

on anaerobic culture. After *Mycoplasma* spp., *Pasteurella* spp. (9/26; 34%) was isolated most commonly. No cats in the IAD group had positive bacterial or mycoplasmal growth on culture.

When combining both groups of pneumonia together, aerobic gram-negative organisms were cultured more often than aerobic gram-positive organisms (Table 5). *Pasteurella* spp. were the gram-negative bacterial organisms isolated most frequently, and *Streptococcus* spp. were the gram-positive organisms isolated most frequently.

Bronchoalveolar fluid cytology slides were available for review in 31 cats (5 AP and 26 BP) and were interpreted as septic with concordant positive culture results in 25, 2 with AP and 23 with BP. Two cats diagnosed with AP had mild to moderate neutrophilic inflammation identified on BAL fluid cytology with absence of observable intracellular organisms and absent to mild neutrophil karyolysis, which was not supportive of sepsis. Both of these cats had recurrent AP; 1 cat had an esophageal stricture and *Staphylococcus* spp. was isolated on culture, and the other had a noninflammatory myopathy causing deglutition abnormalities, and *Peptostreptococcus* spp. was cultured from BAL fluid of this cat, and positive response to antimicrobial treatment was reported. One cat diagnosed with AP and 3 cats with BP had negative cultures but cytologic evidence of airway sepsis including presence of intracellular bacteria and mild to moderately degenerate neutrophils in BAL fluid.

Mycoplasma-like organisms were identified cytologically in 10/11 cats with BP that cultured positive for *Mycoplasma* spp. from BAL fluid. Organisms that appeared similar to *Mycoplasma* spp. were seen in BAL fluid cytology of 3 cats that cultured negative for the organism. Extracellular *Mycoplasma*-like organisms often were admixed with debris and mucus and not identifiable with lower power objective lenses, requiring use of the $\times 100$ lens for confident identification. Confident identification of intracellular *Mycoplasma*-like organisms also required use of the $\times 100$ objective lens, and *Mycoplasma*-like organisms were not seen in the BAL fluid of any cats with AP.

4 | DISCUSSION

We found substantial overlap in clinical manifestations of disease among cats with pneumonia and IAD, but we identified key features that distinguished cats with AP. Primarily, cats with AP were more likely to have an acute history of disease with a median duration of clinical signs of <2 weeks compared to 6 to 9 months for cats with BP or IAD. Also, a minority of cats with AP were presented with cough, and they were more likely to have a history of tachypnea reported by the owners. This finding is similar to a previous report of cats with AP where only 14% were presented with cough and 29% were presented for increased respiratory effort.³ In comparison, a study of dogs with AP reported a 57% prevalence of cough.²⁰

Most cats diagnosed with AP had structural or functional gastrointestinal disease identified, which likely led to decreased calorie intake and consequent lower body weight and body condition scores than observed in cats with BP or IAD. Cats with AP also were more likely to be hypothermic at presentation (40%), possibly because of

severe, peracute disease. The percentage of cats with hypothermia was higher than reported in a previous study, where 11% of cats were hypothermic at presentation.³ The reason for this difference is not clear but might relate to a difference in the study populations, with more severely affected cats presenting to our hospital during the study period.

The clinical presentation of cats with BP was similar to that of cats with IAD. These cats often had a long history of clinical signs characterized by chronic cough, which is surprising, given that infectious disease might be anticipated to result in more emergent signs. It is possible that a sedentary lifestyle of cats obscured clinical disease, cough was less notable than it tends to be in dogs, or the lack of a systemic response caused disease to remain unrecognized in some cats. Interestingly, cats with BP were more likely to have a history of wheezing reported by their owners than were cats with either AP or IAD. Regardless, the clinical similarities between cats with BP and IAD underscore the need for airway sampling to make an accurate diagnosis and provide appropriate treatment.

In the population of cats with AP, gastrointestinal disease was the most common risk factor identified (76%), with esophageal dysfunction identified most commonly. Esophageal dysfunction is challenging to diagnose in cats and might contribute to poor recognition of AP. Twenty-seven percent of cats with AP in our study had a recent history of general anesthesia. A recent study of AP in cats found similar percentages of cats having a known history of gastrointestinal disease or recent general anesthesia.³ When comparing our study to studies in dogs, laryngeal dysfunction and chronic metabolic disease were reported less frequently, and a history of recent general anesthesia was identified more frequently.^{12,13}

Cats with AP had higher peripheral blood neutrophil counts and were more likely to have a left shift than were cats with IAD. Radiographically, they were more likely to have a multifocal, and often severe, alveolar pattern than were cats with IAD. They also tended to have a less severe bronchial pattern than cats with BP. Right middle lung lobe consolidation was identified in 14% of cats in our study with similar prevalence in each group, which negates the utility of this finding in making a diagnosis of AP in cats as is often done in dogs.^{12,13} Right middle lobe consolidation previously has been reported in cats with IAD, and likely reflects mucus plugging and subsequent atelectasis.¹⁵ Interestingly, radiographic evidence of bronchiectasis was present in 43% of all cats in our study. Bronchiectasis has been reported to be the consequence of either chronic infectious or inflammatory airway disease, and our study supports the association of radiographic evidence bronchiectasis with either process, with a prevalence higher than previously published.^{21,22}

In the immediate postairway sampling period, it can be difficult to determine the optimal treatment for cats evaluated for lower respiratory signs. In our study, 87% of cats with BP that underwent bronchoscopic BAL had cytologic evidence of airway sepsis, suggesting that BAL fluid cytology is a key indicator of BP. This percentage is higher than reported in dogs with lower respiratory tract infection, where cytologic evidence of airway sepsis was identified in 74% of cases.²³ Conversely, 2/5 cats with AP lacked evidence of septic inflammation

on retrospective review of their BAL fluid whereas only 1/9 that had airway culture performed had negative results, suggesting that the acute history of disease in these cats might result in presentation before development of cytologically detectable septic inflammation. It also might suggest that acid aspiration plays a critical role in the generation of clinical signs, rather than just bacterial infection, as has been suggested with aspiration in other species. This observation could be taken as evidence for the need to collect an airway sample to confirm the need for antimicrobial treatment, although stability for anesthesia and the risk of a second aspiration event must also be taken into consideration. Because relatively few cats with AP had airway sampling performed, it is possible that sampling bias resulted in higher numbers of cats with septic inflammation or positive cultures than is representative of the population.

In our study, 83% of cats with AP and BP that had airway sampling cultured positive for at least 1 bacterial species, similar to what has been reported in dogs with lower respiratory tract infections.^{13,23} In those studies, a single bacterial species was identified in 42% to 44% of dogs, compared to 29% of cats in our study.^{13,23} In our study, aerobes were cultured more frequently than anaerobes, and *Pasteurella* spp. were the most frequently isolated bacteria in cats with either type of pneumonia (35% of all pneumonia cats).

Aerobic bacteria cultured from cats with BP were similar to previous reports, but we detected anaerobic bacteria in 3/9 cats with AP and 7/26 cats with BP (30% of all cats). These numbers are higher than what has been reported in either cats or dogs previously.^{8,13,23} It is not immediately evident why anaerobic bacteria were cultured more frequently in our study population, but it might reflect the common performance of anaerobic cultures in our hospital. It is also possible that the chronic duration observed in many of the cats with BP promoted an oxygen-deprived environment more suitable for anaerobic growth. Mucus plugging is common in cats with lower airway disease in general and might have resulted in a more anaerobic environment. Finally, the source of infection in cats with BP is unclear and might be related to the general population of bacteria commonly found in cats, which is rich in anaerobes.²⁴

Mycoplasma spp. were isolated in 41% of cats with BP compared to no cats with AP. This finding was unexpected given the presence of *Mycoplasma* spp. on mucosal surfaces, including the oral cavity. Additionally, *Mycoplasma*-like organisms were identified intracellularly on cytologic examination in 13 cats with BP, 10 of which had subsequent positive *Mycoplasma* culture, and 3 of which did not. *Mycoplasma* are very small, pleomorphic organisms and easily can elude identification on BAL fluid cytologic assessment. In fact, organisms were not identified in 4/13 cases initially, but were seen when reviewed retrospectively, emphasizing the importance of careful microscopic examination at $\times 100$ magnification. Only 2 cats had pure growth of *Mycoplasma* spp. on culture. Both had markedly suppurative inflammation but only mild to moderate neutrophil karyolysis on BAL fluid cytology; 1 of these cats had *Mycoplasma*-like organisms observed cytologically.

A previous evaluation of the role of *Mycoplasma* in lower respiratory tract disease of cats found no difference in culture or PCR

positivity between cats with IAD and healthy controls, with PCR apparently more sensitive than culture.²⁵ Although our study did not include healthy control cats, cats with IAD in our study all had negative *Mycoplasma* culture, and the number of cats with BP that were culture positive and cytologically positive for *Mycoplasma*-like organisms supports a role for this organism in pneumonia in cats.

Our study was not intended to assess antimicrobial treatment used or outcomes for these cats, but the microbiologic findings reported here may be helpful in guiding empirical treatment for cats with either AP or BP. Given the relatively high incidence of positive anaerobic bacterial and *Mycoplasma* cultures in cats with BP, antimicrobials that provide coverage for these types of bacteria are warranted while awaiting culture results. Conversely, aerobic bacteria were more common in cats with AP and there was a notable lack of *Mycoplasma* growth or cytologic identification from airway samples in these cats.

As with any retrospective study, there are limitations in the amount and type of data that can be extracted from medical records, specifically owner-reported history and clinical signs. Additionally, although all cats included in the AP group had a clinical diagnosis by the attending veterinarian of AP only a small number of cats had airway samples collected, potentially leading to mis-categorization of some of these cats. In our study, computed tomography was performed rarely, and the data were not collected for our study, limiting our assessment of bronchiectasis beyond radiographic interpretation. Studies that perform multiple comparisons among study populations are prone to type I error. We attempted to limit type I error by performing post hoc analyses when possible. Despite these limitations, our data increase knowledge of the clinical signs and diagnostic findings in cats with pneumonia.

In conclusion, we report clinical findings in a large group of cats with BP and AP. Aspiration pneumonia should be suspected in cats with a concurrent history of gastrointestinal disease or weight loss and short duration of respiratory clinical signs characterized mainly by increased respiratory rate. Conversely, BP mimics many of the clinicopathologic and radiographic features of IAD in cats, and these cats require bronchoscopy or other means of airway sampling to render an accurate diagnosis and determine optimal antimicrobial treatment. Finally, our study emphasizes that *Mycoplasma* spp. appear to play an important role in lower respiratory tract infections in cats and that diligent high power ($\times 100$ objective lens) cytologic assessment can identify these organisms. The role of culture versus PCR in these *Mycoplasma*-infected cats requires further study.

ACKNOWLEDGMENTS

No funding was received for this study. Data from this project were presented at the 2020 ACVIM Forum On Demand.

CONFLICT OF INTEREST DECLARATION

Dr Dear has consulted with Antech Diagnostics but the project described is not related to this work. No other authors have a conflict of interest.

OFF-LABEL ANTIMICROBIAL DECLARATION

This study did not evaluate the use of antimicrobials for cats with pneumonia, but there is mention that cats were included in the aspiration pneumonia group if their condition improved with various antimicrobials including azithromycin, amoxicillin or amoxicillin-clavulanic acid, cefazolin, enrofloxacin, or a combination thereof.

INSTITUTIONAL ANIMAL CARE AND USE COMMITTEE (IACUC) OR OTHER APPROVAL DECLARATION

Authors declare no IACUC or other approval was needed.

HUMAN ETHICS APPROVAL DECLARATION

Authors declare human ethics approval was not needed for this study.

ORCID

Jonathan D. Dear  <https://orcid.org/0000-0002-7166-1442>

Lynelle R. Johnson  <https://orcid.org/0000-0002-5331-5626>

REFERENCES

1. *Stedman's Medical Dictionary*. Baltimore, MD: Lippincott Williams & Wilkins; 2016.
2. Tenwolde AC, Johnson LR, Hunt GB, Vernau W, Zwingenberger AL. The role of bronchoscopy in foreign body removal in dogs and cats: 37 cases (2000-2008). *J Vet Intern Med*. 2010;24:1063-1068.
3. Levy N, Ballegeer E, Koenigshof A. Clinical and radiographic findings in cats with aspiration pneumonia: retrospective evaluation of 28 cases. *J Small Anim Pract*. 2019;60:356-360.
4. Mandell LA, Niederman MS. Aspiration pneumonia. *N Engl J Med*. 2019;380:651-663.
5. Rex MA. The production of laryngospasm in the cat by volatile anaesthetic agents. *Br J Anaesth*. 1970;42:941-947.
6. McKeever T, Harrison TW, Hubbard R, Shaw D. Inhaled corticosteroids and the risk of pneumonia in people with asthma: a case-control study. *Chest*. 2013;144:1788-1794.
7. Lee AS, Ryu JH. Aspiration pneumonia and related syndromes. *Mayo Clin Proc*. 2018;93:752-762.
8. Bart M, Guscetti F, Zurbriggen A, et al. Feline infectious pneumonia: a short literature review and a retrospective immunohistological study on the involvement of *Chlamydia* spp. and distemper virus. *Vet J*. 2000;159:220-230.
9. Macdonald ES, Norris CR, Berghaus RB, Griffey SM. Clinicopathologic and radiographic features and etiologic agents in cats with histologically confirmed infectious pneumonia: 39 cases (1991-2000). *J Am Vet Med Assoc*. 2003;223:1142-1150.
10. Johnson LR, Drazenovich TL. Flexible bronchoscopy and bronchoalveolar lavage in 68 cats (2001-2006). *J Vet Intern Med*. 2007;21:219-225.
11. Foster SF, Martin P, Braddock JA, Malik R. A retrospective analysis of feline bronchoalveolar lavage cytology and microbiology (1995-2000). *J Feline Med Surg*. 2004;6:189-198.
12. Kogan DA, Johnson LR, Sturges BK, Jandrey KE, Pollard RE. Etiology and clinical outcome in dogs with aspiration pneumonia: 88 cases (2004-2006). *J Am Vet Med Assoc*. 2008;233:1748-1755.
13. Tart KM, Babski DM, Lee JA. Potential risks, prognostic indicators, and diagnostic and treatment modalities affecting survival in dogs with presumptive aspiration pneumonia: 125 cases (2005-2008). *J Vet Emerg Crit Care*. 2010;20:319-329.
14. Dear JD. Bacterial pneumonia in dogs and cats: an update. *Vet Clin North Am Small Anim Pract*. 2020;50:447-465.
15. Foster SF, Allan GS, Martin P, Robertson ID, Malik R. Twenty-five cases of feline bronchial disease (1995-2000). *J Feline Med Surg*. 2004;6:181-188.
16. Kirschvink N, Leemans J, Delvaux F, Snaps F, Clercx C, Gustin P. Functional, inflammatory and morphological characterisation of a cat model of allergic airway inflammation. *Vet J*. 2007;174:541-553.
17. Lee EA, Johnson LR, Johnson EG, Vernau W. Clinical features and radiographic findings in cats with eosinophilic, neutrophilic, and mixed airway inflammation (2011-2018). *J Vet Intern Med*. 2020;34:1291-1299.
18. Hawkins EC, Kennedy-Stoskopf S, Levy J, et al. Cytologic characterization of bronchoalveolar lavage fluid collected through an endotracheal tube in cats. *Am J Vet Res*. 1994;55:795-802.
19. Ybarra WL, Johnson LR, Drazenovich TL, Johnson EG, Vernau W. Interpretation of multisegment bronchoalveolar lavage in cats (1/2001-1/2011). *J Vet Intern Med*. 2012;26:1281-1287.
20. Kogan DA, Johnson LR, Jandrey KE, Pollard RE. Clinical, clinicopathologic, and radiographic findings in dogs with aspiration pneumonia: 88 cases (2004-2006). *J Am Vet Med Assoc*. 2008;233:1742-1747.
21. Norris CR, Samii VF. Clinical, radiographic, and pathologic features of bronchiectasis in cats: 12 cases (1987-1999). *J Am Vet Med Assoc*. 2000;216:530-534.
22. Bachman AL, Hewitt WR, Beekley HC. Bronchiectasis; a bronchographic study of sixty cases of pneumonia. *AMA Arch Intern Med*. 1953;91:78-96.
23. Johnson LR, Queen EV, Vernau W, Sykes JE, Byrne BA. Microbiologic and cytologic assessment of bronchoalveolar lavage fluid from dogs with lower respiratory tract infection: 105 cases (2001-2011). *J Vet Intern Med*. 2013;27:259-267.
24. Dorn ES, Tress B, Suchodolski JS, et al. Bacterial microbiome in the nose of healthy cats and in cats with nasal disease. *PLoS One*. 2017;12:e0180299.
25. Schulz BS, Richter P, Weber K, et al. Detection of feline *Mycoplasma* species in cats with feline asthma and chronic bronchitis. *J Feline Med Surg*. 2014;16:943-949.

How to cite this article: Dear JD, Vernau W, Johnson EG, Hulsebosch SE, Johnson LR. Clinicopathologic and radiographic features in 33 cats with aspiration and 26 cats with bronchopneumonia (2007-2017). *J Vet Intern Med*. 2021; 35:480-489. <https://doi.org/10.1111/jvim.16005>